




## SMALL RUMINANT ISSUE



### Inside this issue:

#### ■ Goats

- Congenital hepatic portosystemic shunt
- Abomasal parasitism
- *Mannheimia haemolytica*
- Enterotoxemia
- *Pseudomonas mastitis*
- Goiter
- *Chlamydia* sp. and *Campylobacter jejuni*
- *Listeria monocytogenes* septicemia

#### ■ Sheep

- *Cryptosporidium* sp.
- *Actinobacillus lignieresii* and *Pasteurella multocida*
- *Mannheimia haemolytica* mastitis, embolic pneumonia and septicemia

#### ■ Routine Scrapie Surveillance

In early 2019, CAHFS' on-line client survey found 30% of respondents were sheep, goat and/or camelid owners, and another 19% were small ruminant veterinary practitioners. In addition, CAHFS has noted a steady increase in submissions of small ruminant samples for routine herd monitoring like caprine arthritis encephalitis (CAE) and caseous lymphadenitis (CL) serology and fecal parasite checks as well as tissues for a variety of tests and animals for necropsy. In order to share more information about our small ruminant cases, this special issue encompasses the most interesting cases received, both common and uncommon diseases, and unusual presentations of common agents from cases received over the past 3 months.

### Goats

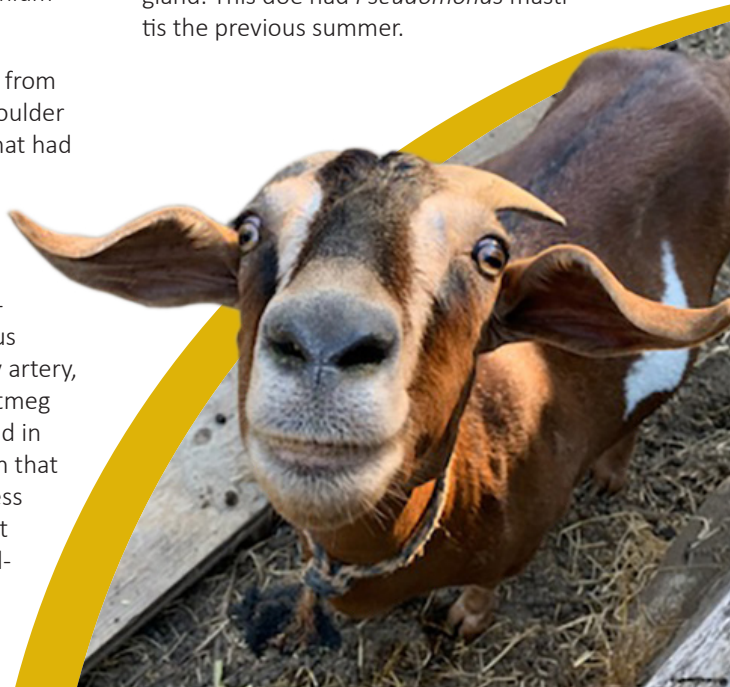**Congenital hepatic portosystemic shunt** was diagnosed in 6-month-old Nigerian Dwarf goat with a 4-week history of weight loss, anorexia, hiding behavior, jaundice, markedly elevated bilirubin and progressive weakness. This syndrome has been reported in Boer, Nigerian Dwarf, Saanen, Toggenburg and some mixed breed goats.

**Abomasal parasitism** caused anemia, diarrhea and emaciation in an adult female goat. Mucosal abomasal hyperplasia and hepatic centrilobular necrosis were observed on necropsy and histopathology, respectively. *Haemonchus* sp. and *Teladorsagia* sp. were observed in the abomasum. *Corynebacterium pseudotuberculosis* was isolated from a large abscess in the caudal mediastinal lymph node encroaching on the distal esophagus. This goat also had bronchopneumonia and severe copper and selenium deficiencies.

***Mannheimia haemolytica*** was isolated from a **pulmonary arterial thrombus** and shoulder **abscess** in a 2-year-old Oberhasli doe that had kidded 3 weeks earlier, and had not recovered well after delivery. The animal had a low-grade fever, developed front-end edema and died 3 weeks after onset of signs despite treatment. At necropsy, a 6 cm long thrombus was occluding the thickened pulmonary artery, resulting in myocardial hypertrophy, nutmeg liver, lower parts edema, and excess fluid in the pericardial sac, thorax and abdomen that clotted on exposure to air. A 2 cm abscess was present in the sub-cutis on the right shoulder. Histology revealed chronic pulmonary arteritis and liver heart failure lesions.

**Enterotoxemia** was diagnosed in a 5-week-old Boer buck that died suddenly. Postmortem examination revealed blood fluid in the intestine. *Clostridium perfringens* type D enterotoxemia was diagnosed based on detection of epsilon toxin by ELISA in intestinal contents. Typical perivascular edema in the brain and superficial mucosal necrosis in the small intestine with large numbers of bacilli were seen on microscopic examination. A 3-year-old doe died of bloat the same day. Both goats were on a high quality dairy hay and were copper and selenium deficient.

***Pseudomonas mastitis*** caused the death of a 4-year-old milking doe that developed a high fever shortly after giving birth to triplets. Despite extensive treatment the doe died two days later. At necropsy, the udder was markedly enlarged and mottled dark red. *Pseudomonas aeruginosa* was isolated from the mammary gland. This doe had *Pseudomonas mastitis* the previous summer.





## Lab Locations:

### CAHFS – Davis

University of California  
620 West Health Sciences Dr.  
Davis, CA 95616  
Phone: 530-752-8700  
Fax: 530-752-6253  
daviscahfs@ucdavis.edu

### CAHFS – San Bernardino

105 W. Central Ave.  
San Bernardino, CA 92408  
Phone: 909-383-4287  
Fax: 909-884-5980  
sanbernardinocahfs@ucdavis.edu

### CAHFS – Tulare

18760 Road 112  
Tulare, CA 93274  
Phone: 559-688-7543  
Fax: 559-688-2985  
tularecahfs@ucdavis.edu

### CAHFS – Turlock

1550 N. Soderquist Road  
Turlock, CA 95381  
Phone: 209-634-5837  
Fax: 209-667-4261  
turlockcahfs@ucdavis.edu

**Goiter** was diagnosed in two premature goat kids from a 3-year-old, second-freshening doe. The thyroid glands were markedly enlarged. Both kids also had severe selenium deficiency. Goiter can be caused by iodine deficiency, substances that interfere with the uptake of dietary iodine (goitrogens) or rarely by iodine excess. Goitrogens include brassicas (cabbage, rape, mustard and kale) and soybeans. Affected kids can be born with enlarged thyroid glands, weakness and/or poor hair coat, and may die within hours of birth.

**Chlamydia sp.** and **Campylobacter jejuni** caused the **premature birth** of a kid from a flock with a history of late-term abortions, premature births and neonatal death, in three does, respectively. The placenta had intercotyledonary placentitis and *Chlamydia* sp. was detected by immunohistochemistry. *C. jejuni* was isolated from the abomasum and placenta.

**Listeria monocytogenes septicemia** in a 1-week-old Pygmy goat doe caused high fever, irregular heartbeat, rapid respiration, increased vocalization, lethargy and death. On necropsy, the liver, spleen and adrenal glands had multiple, slightly raised, small white foci. The lungs were congested, edematous and had 2-3mm dark depressed foci. Histologically, the foci seen grossly in different organs consisted of areas of necrosis with gram-positive rods. *Listeria monocytogenes* was isolated from the spleen and liver.

### Sheep

**Cryptosporidium sp.** was the cause of severe **diarrhea** and death in five of six baby lambs submitted for necropsy and diagnostic work-up. The five lambs had gassy, yellow liquid filling the intestines and cryptosporidia in prominent numbers were observed on microscopy. Cryptosporidia are zoonotic protozoa. *Cryptosporidium parvum* is the most commonly identified species often associated with diarrhea in calves and dairy goats. The sixth lamb had severe bronchopneumonia; *Mannheimia haemolytica* and *Trueperella pyogenes* were isolated from the lungs.

**Actinobacillus lignieresii** and **Pasteurella multocida** type A caused rhinitis leading to difficulty breathing, eating and drinking in a mixed breed ewe. Over a 6-week period, five sheep in a flock of 1,000 were affected and three died. On necropsy, the muzzle and right side of the face were swollen and alopecic, and had doughy texture and crusts. The nasal turbinates, cribriform plate and lungs had raised miliary nodules. Microscopically, these nodules, the retropharyngeal lymph nodes, facial skin, lips and subcutis had pyogranulomas with splendore-hoepli reaction. *A. lignieresii* and *P. multocida* were isolated from the nasal cavity. The ewe had concurrent *Staphylococcus* spp. mastitis and severe hepatic lipidosis.

**Mannheimia haemolytica mastitis, embolic pneumonia and septicemia** were the cause of sudden death of a 6-year-old Suffolk ewe that had lambed one month prior to death. The organism was isolated from the mammary gland.

### ROUTINE SCRAPIE SURVEILLANCE

CAHFS routinely submits brain and lymph node samples from necropsy cases of sheep and goats between 1.5 and 8 years of age for scrapie testing as part of the National Scrapie Eradication program in order to meet international standards and state targets for surveillance. This testing can also help individual flock and herd owners to document their scrapie-free status. The USDA Scrapie annual report is available on the [USDA's web site](#).

