

Equine Edition

CAHFS

CONNECTION

March 2014

Inside this issue:

- Ulcerative enterocolitis
- *Actinobacillus* and *Streptococcus*
- *Clostridium* type C and *C. difficile* co-infection
- Colitis—NSAIDs
- Roundworm impaction and rupture
- Bristle grass oral lesions
- Senecio toxicosis
- Oleander toxicosis
- Drought related problems
- *Corynebacterium pseudotuberculosis* abscesses

These items are re-printed from earlier issues of CAHFS Connection.

Holiday Schedule

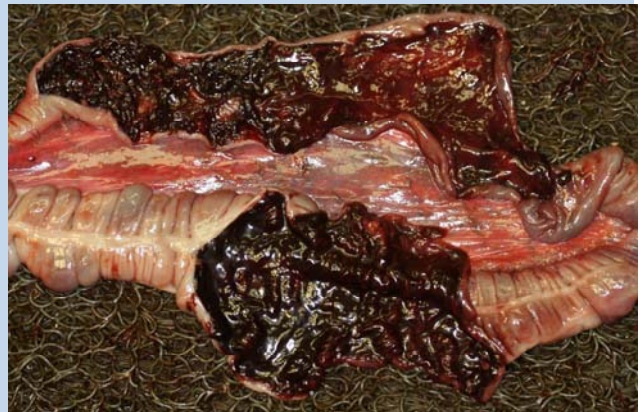CAHFS will be open but will have limited services on **Friday, March 28, 2014** in observance of Cesar Chavez day.

Please contact your laboratory to plan your testing needs accordingly.

Ulcerative enterocolitis and typhlocolitis associated with *Actinobacillus equuli* and *Streptococcus equi* are occasionally observed in both foals and adult horses and clinical signs may be enteric (colic, diarrhea) or non-specific (depression, off feed, fever, and death). Some horses may develop secondary septicemia. In cases of colitis associated with *Actinobacillus equuli* and *Streptococcus equi*, findings are often well defined, ulcers over lymphoid patches (GALT) scattered throughout the large colon, usually associated with large numbers of bacteria over the ulcers. These multifocal ulcers are different from the diffuse or regionally extensive damage described for the most frequently identified bacterial pathogens of horses, namely *Clostridium perfringens* type C, *Clostridium difficile* and *Salmonella* sp. Although not among the common causes of bacterial colitis in horses, *Actinobacillus* sp. and *Streptococcus* sp. may be opportunistic intestinal pathogens of horses and should be considered as differential diagnoses in cases of equine intestinal disease.

Six foals, between 1-day and 1-week-old submitted to CAHFS for necropsy and diagnostic work up had clinical histories of colic and diarrhea, followed by acute death. None of these animals had received antibiotics. Necropsy revealed hemorrhagic and necrotizing **enter-typhlo-colitis**. A diagnosis of **co-infection with *C. perfringens* type C and *C. difficile*** was made based on detection of beta toxin of *C. perfringens* and *C. difficile* toxins A/B in intestinal content of these animals, by ELISA. *Clostridium perfringens* type C is one of the most important causes of enteritis in newborn foals. *C. difficile* is now recognized as an im-

portant cause of enterocolitis in horses of all ages; the most important predisposing factor being antibiotic treatment. While infections by *C. perfringens* type C or *C. difficile* are frequently seen in foals, diagnosis of concurrent infection by these two agents was rare. Because none of the foals had received antibiotic therapy, the predisposing factor for the *C. difficile* infection remains undetermined; it is possible that the *C. perfringens* infection acted as a predisposing factor for *C. difficile* or vice versa. These cases also stresses the need to perform a complete diagnostic work-up in all cases of foal digestive disease even when one causative agent has already been identified.



Diffuse hemorrhagic colitis (large colon open sections) in 1-day-old foal with *C. perfringens* type C and *C. difficile* co-infection.

Right dorsal colitis, presumably produced by **non-steroidal anti-inflammatory drugs** (NSAIDs) was diagnosed in a 4-year-old Thoroughbred gelding horse that was euthanized after 36 hours of **colic**. The horse had been treated with large doses of NSAIDs before the onset of colic. *Clostridium difficile*, *Clostridium perfringens*, *Salmonella* spp. and intestinal parasites were ruled out. A diagnosis of NSAIDs colitis is usually based on ruling out other causes of colitis coupled with gross lesions and a clinical history of NSAIDs treatment.

CAHFS Lab Locations

CAHFS - Davis

University of California
West Health Sciences Drive
Davis, CA 95616
Phone: 530-752-8700
Fax: 530-752-6253
cahfsdavis@cahfs.ucdavis.edu

CAHFS - San Bernardino

105 W. Central Avenue
San Bernardino, CA 92408
Phone: (909) 383-4287
Fax: (909) 884-5980
cahfs-sanbernardino@cahfs.ucdavis.edu

CAHFS - Tulare

18830 Road 112
Tulare, CA 93274
Phone: (559) 688-7543
Fax: (559) 686-4231
cahfstulare@cahfs.ucdavis.edu

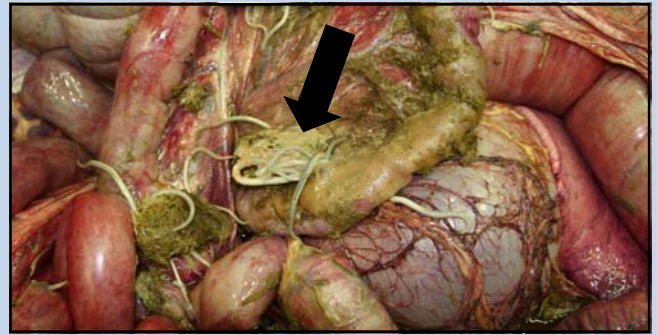
CAHFS—Turlock

1550 Soderquist Road
Turlock, CA 95381
Phone: (209) 634-5837
Fax: (209) 667-4261
cahfsturlock@cahfs.ucdavis.edu

Your feedback is always welcome. To provide comments or to get additional information on any of the covered topics or services, please contact Sharon Hein at slhein@ucdavis.edu.

We're on the Web
www.cahfs.ucdavis.edu

Roundworm (*Parascaris equorum*) intestinal impaction with over 500 worms resulted in small intestine **rupture** in a juvenile colt. The colt was found down with colic and abnormal lung sounds and died from peritonitis secondary to the perforation. In addition, the horse had lung lesions that may have been from ascarid larval migration.



Intestinal rupture (arrow) from roundworms. Green feed, worms and fibrin on surface of small intestine (peritonitis).

Bristlegrass (*Setaria pumila*) and foxtail barley (*Hordeum jubatum*) was detected in hay fed to two crossbred adult horses with tongue and oral ulcers. Penetration of the mucosa by the barbed, sharp awns from these plants was the probable cause of the ulcers. Oral changes can mimic Vesicular Stomatitis Virus in horses.

Pyrolizidine alkaloid (PA) toxicosis from exposure to *Senecio vulgaris* (common groundsel) caused **liver failure** in a Quarter horse mare. The mare and her pen mate had a 2-3 week history of progressive jaundice, depression and being off feed with marked increase of liver enzymes and declining albumen indicative of liver failure. Microscopic exam of the liver of the mare was typical for PA toxicosis. *Senecio* was found in hot spots in the July cutting of hay on the premise. *Senecio* sp., a common weed in hayfields, contains PA which causes irreversible liver damage. In many cases, clinical signs of chronic PA poisoning do not appear for 2-8 months after initial ingestion of PA-containing plants. Neurologic signs ("walking disease") from liver failure may be seen in horses. Once clinical signs are observed, the prognosis is poor.

Oleander toxicosis and **selenium deficiency** were the cause of severe **heart disease** in an adult Quarter horse gelding. The horse had been lethargic for three days and developed a rapid and irregular heart beat and was euthanized. A pasture mate developed acute staggering and died. Oleandrin was detected in the liver. A concurrent hepatitis of unknown cause was found and was the cause of jaundice seen at necropsy. Yard clippings with oleander were found in the pasture.

Drought conditions may cause animals to graze closer to the soil increasing the risk of inhaling or ingesting anthrax spores. If you suspect anthrax, remove the whole eye or aseptically collect aqueous humor and submit it in a sealed tube for culture. Prevention by **vaccination of animals that graze in anthrax endemic areas is highly recommended**. Drought can also result in animals ingesting **toxic plants** due to lack of their usual forages. CAHFS website has an article on drought associated plant toxicosis at www.cahfs.ucdavis.edu where you can also find the CDFA fact sheet on anthrax.

Corynebacterium pseudotuberculosis is a clinically and economically significant disease in horses in dry regions like California and Texas. Several clinical forms are observed in horses: external abscesses often in the pectoral and sheath regions; internal abscesses; both internal and external abscesses; and ulcerative lymphangitis of the distal limbs. Serology (serum synergistic hemolysis inhibition – SHI test) is the most commonly used method to detect the presence of internal abscesses, but interpretation of the titers remains challenging. In a retrospective study of horses at the UC Davis Veterinary Medicine Teaching Hospital, high *C. pseudotuberculosis* titers were present in horses with active infection (internal and/or external). Thus, high titers on SHI without presence of external abscess are suggestive of internal abscessation. Moderate titers were observed in horses with external abscesses (with or without concurrent internal abscesses), and in some uninfected horses. A serologic result of 1:64 was found in a 3-year-old mare with a resolving external abscess due to *C. pseudotuberculosis*. The horse was improving when she lost hind limb control, collapsed and was euthanized. On necropsy exam, **multiple abscesses** in the lungs, heart and liver were positive for *C. pseudotuberculosis*.