

## Inside this issue:

- **Bovine**
  - *Salmonella* Dublin septi-cemia
  - Clostridial myocarditis or myositis
- **Equine**
  - Pyrrolizidine alkaloid tox-icosis
- **Pig**
  - Mulberry heart disease
- **Small Ruminant**
  - Arthrogyposis and scoli-osis—goat
  - Cache valley virus-sheep
- **Poultry/Other Avian**
  - Necrotic enteritis - chick-ens
  - Infectious bronchitis virus
    - chickens
  - Sinusitis and air sacculitis - turkey
  - *Yersinia pseudotuberculo-sis* - doves
  - Avian Bornavirus - parrot

## HOLIDAY SCHEDULE

CAHFS will be closed on Monday, May 25, 2015 in observance of Memorial Day. Please contact your laboratory to plan your testing needs accordingly.

## Bovine

***Salmonella* Dublin septicemia** was diagnosed in a group of calves exposed to heavy smoke for four days from a fire adjacent to the calf ranch. Approximately 25% of the calves had respiratory signs including coughing and some had high fevers. One 2-month-old calf submitted for necropsy had wet heavy lungs, swollen liver and enlarged spleen. *Salmonella* Dublin was isolated from the liver; microscopic changes were also consistent with *Salmonella* septicemia. No lesions attributable to smoke were seen in the lung but the fire and associated smoke probably acted as stress factors. *Salmonella* Dublin septicemia is found in 30- to 90-day-old calves that often exhibit high fever and respiratory signs with or without diarrhea.

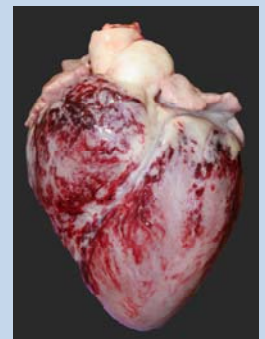
**Clostridial myocarditis or myositis** was diagnosed in two 9-month-old Holstein heifers and a 5-month-old beef steer on separate premises. On the dairy, six heifers died suddenly in four days and one was down. On the beef operation, the affected calves were slow to get up and reluctant to move and seven in a group of 65 had died in eight days. Both dairy animals had severe **myocarditis** with fibrinous epicarditis while the steer had cervical and lumbar myositis. ***Clostridium chauvoei*** was detected in all three animals by culture and fluorescent antibody testing on impression smears from affected sites.

## Equine

**Pyrrolizidine alkaloid (PA) toxicosis** caused anorexia, depression, weight loss and death in six horses in a group of approximately 25, over a 2-month period. A yearling Quarter Horse carcass submitted for necropsy and tissue samples from two other horses from the same ranch had **liver lesions** consistent with PA toxicity. Samples of the hay that was fed during the previous six months was heavily contaminated with common groundsel (*Senecio vulgaris*) and very small amounts of fiddleneck (*Amsinckia intermedia*), both PA-accumulating plants. PA (Senecionine and Seneciphylline) were detected in the hay. PAs cause progressive destruction of the liver over several months before signs of illness and death occur. In California, PA toxicity usually occurs when animals are fed first cut alfalfa hay contaminated with common groundsel.

## Pig

**Vitamin E deficiency** caused severe cardiac hemorrhage and myocardial necrosis (**mulberry heart disease**) in a 112-pound gilt that was sluggish, developed seizures and died within 24-hours. Another pig on the premises with similar signs also died, but was not submitted for necropsy. On gross examination, the pericardial sac was filled with abundant serofibrinous fluid, and the heart was diffusely pale and had severe epicardial, myocardial and endocardial hemorrhages. Vitamin E concentration in the liver was 0.46 ppm (normal for this age is > 1.5 ppm).



Mulberry heart disease  
in a pig

## CAHFS Lab Locations

### CAHFS - Davis

University of California  
620 West Health Sciences Drive  
Davis, CA 95616  
Phone: 530-752-8700  
Fax: 530-752-6253  
[cahfsdavis@cahfs.ucdavis.edu](mailto:cahfsdavis@cahfs.ucdavis.edu)

### CAHFS - San Bernardino

105 W. Central Avenue  
San Bernardino, CA 92408  
Phone: (909) 383-4287  
Fax: (909) 884-5980  
[cahfs-sanbernardino@cahfs.ucdavis.edu](mailto:cahfs-sanbernardino@cahfs.ucdavis.edu)

### CAHFS - Tulare

18830 Road 112  
Tulare, CA 93274  
Phone: (559) 688-7543  
Fax: (559) 686-4231  
[cahfstulare@cahfs.ucdavis.edu](mailto:cahfstulare@cahfs.ucdavis.edu)

### CAHFS—Turlock

1550 Soderquist Road  
Turlock, CA 95381  
Phone: (209) 634-5837  
Fax: (209) 667-4261  
[cahfsturlock@cahfs.ucdavis.edu](mailto:cahfsturlock@cahfs.ucdavis.edu)

---

---

Your feedback is always welcome. To provide comments or to get additional information on any of the covered topics or services, please contact Sharon Hein at [shein@ucdavis.edu](mailto:shein@ucdavis.edu).

---

---

We're on the Web  
[www.cahfs.ucdavis.edu](http://www.cahfs.ucdavis.edu)

## Small Ruminant

**Arthrogryposis and scoliosis** were associated with dystocia in an Alpine cross doe and her full sibling within a 2-day period. Arthrogryposis is associated with Bluetongue, Schmallenberg, Akabane and Cache Valley viral infections, all of which were ruled out. Ingestion of toxic plants such as tree tobacco, lupine, poison hemlock, lathyrus and locoweed by the doe at specific times of gestation are also associated with arthrogryposis in the fetus, in addition to genetics. In this case it was assumed that the etiology was one of the toxic plants mentioned or genetics.

**Cache valley virus** caused **defects** of the brain (hydranencephaly) and spinal cord (micromyelia and aplasia), crooked legs, neck and spine and muscle hypoplasia, in a stillborn Southdown lamb submitted for necropsy. A total of four lambs in a flock of 200 ewes had similar lesions. The fetal cerebral spinal fluid had a titer of 1:4 to Cache Valley virus while PCR testing on the brain remnants was negative. This virus is mosquito-transmitted and exposure of ewes early in gestation results in brain and skeletal defects in the fetus. Viruses that infect fetuses early in gestation are often cleared by the time of birth.

## Poultry and Other Avian

**Necrotic enteritis** was diagnosed in three out of five commercial layer hens from a ranch with a history of **increased mortality** over two weeks. An almost pure culture of *C. perfringens* was isolated from the intestinal content of the affected chickens. All the chickens examined had moderate small intestine coccidiosis, considered to be the main predisposing factor of necrotic enteritis, which is caused by *C. perfringens* type A.

A **nephropathogenic strain of Infectious bronchitis virus (IBV)** was the cause of high mortality in 2- to 3-week-old chicks. Approximately 100 out of 240 chicks died within a 1-week period. No respiratory signs were observed. All of the seven chicks necropsied had slightly enlarged, very pale kidneys with urate-filled ureters and diffuse, tan, fine stippling. Histologically, acute nephrosis and subacute interstitial nephritis was found. The diagnosis was confirmed by virus isolation and PCR and the nephropathogenic aspect was demonstrated by finding abundant IBV antigen in the renal tubules and only small amount in the bronchial epithelium by immunohistochemistry.

**Sinusitis and air sacculitis** due to *Avibacterium* sp., *E. coli*, *Mycoplasma gallisepticum* and *M. synoviae* caused a 2-month course of swollen face, respiratory distress and anorexia in a 10-month-old female Narragansett turkey from a flock of three. Necropsy revealed severely distended infraorbital sinuses with mucoïd and caseous exudate and severe abdominal airsacculitis. The bird was PCR and serology positive for *M. gallisepticum* and *M. synoviae*. There was also severe amyloidosis in the liver probably from the chronic inflammation.

**Yersinia pseudotuberculosis** caused **septicemia** in two adult doves that died acutely. Birds were housed in outdoor wire cages on dirt flooring. Histologically, severe multifocal necrosis with bacterial colonies was seen in the liver and spleen. Bacteria were also seen in lungs and kidneys. *Yersinia pseudotuberculosis* was isolated from multiple tissues and was sensitive to most of the antibiotics it was tested against using the Kirby Bauer antimicrobial test. Based on the history, rodents may have played a role in disease transmission to the doves.

**Avian Bornavirus** infection (proventricular dilation syndrome) was diagnosed in a 5-year-old Eclectus parrot. The bird was anorexic, had watery droppings with increased urates, irregular heart rate with extreme bradycardia and harsh bronchovesicular sounds which progressed to sneezing and coughing. On necropsy, the parrot had a distended proventriculus. Ganglioneuritis of the ventriculus, encephalitis and myocardial necrosis was seen on histologic examination. Immunohistochemistry demonstrated avian bornavirus 2 in the brain associated with the inflammation.